

# In-Vivo Optical Strain Measurements of the Human Heart

A. Soltani<sup>1</sup>, J. Lahti<sup>2</sup>, S. Curtze<sup>1</sup>, K. Järvelä<sup>2</sup>, J. Laurikka<sup>2,3</sup>, M. Hokka<sup>1a</sup>, V.-T. Kuokkala<sup>1</sup>

<sup>1</sup>Tampere University of Technology, POB 589, 33101 Tampere, Finland, <sup>2</sup>Tampere University Hospital Heart Center, POB 2000, FI-33521 Tampere, Finland, <sup>3</sup>Tampere University, Faculty of Medicine and Life Sciences

<sup>a</sup>mikko.hokka@tut.fi

## Abstract


Digital image correlation is a suitable method for motion and deformation measurements especially in such cases where physical contact with the measured object is limited. In our previous research [1-2], we have demonstrated that DIC can be used for obtaining full field deformation data of the human heart. In this paper, we present a comparison of the longitudinal strain of the myocardium before and after cardiopulmonary bypass. The results show encouraging feedback and demonstrate that DIC can detect and identify changes in the functioning of the heart during the operation.

## Introduction

Successful open-heart surgery and the following recovery require continuous monitoring and measurements of the workload and functions of the heart, as well as continuous survey of various haemodynamic parameters describing the overall performance of the heart throughout the surgery. The deformation and motion of the heart, especially the right ventricle (RV), are important descriptors of the functionality of the heart. Any abnormalities in the motion or deformation of the RV can be indications of problems related to the heart's ability to circulate blood into the system. For example, increases in the dimensions of the RV after cardiopulmonary bypass (CPB) suggesting reduction in the RV function may also be associated with worsening biventricular function because of interventricular dependence. In most cases, the spontaneous function of the heart is stopped using cardioplegia so that the surgeons can operate on the heart when it is not moving. When the surgical repairs are completed, the spontaneous functions of the heart are returned, and the heart must recover its full functionality before weaning from the CPB. Any unnoticed problems, such as the RV dysfunction can lead to severe complications. It is worth noticing that the overall functionality of the heart is reflected on its motion and deformability either on a local or global scale. However, not all changes indicate problems or reduced functionality of the heart. For example, the longitudinal motion of the RV lateral wall is typically reduced even after uneventful cardiac surgery despite preserved RV ejection fraction and stroke volume. Because of the lack of proper measurement tools, there is a strong scientific motivation to develop better analysis tools for in-vivo measurements of the heart's function and to better understand how the changes in the RV function are reflected in the motion and overall deformability of the heart. This paper presents some recent results and findings of our clinical study, where optical photography and Digital Image Correlation were used to characterize the mechanical deformation of the heart during open-heart surgery.

## Experimental

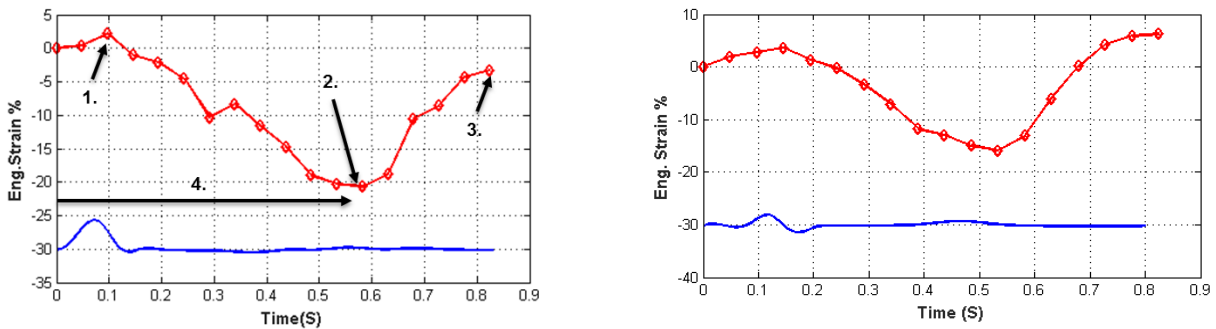
The images discussed in this paper were obtained at Tampere University Hospital Heart Center by installing two LaVision 5MPix Imager E-Lite cameras near the ceiling of the operating room. Approximately 400 images were obtained at 20 Hz covering 15-20 heartbeats before and after the CPB. A stereo pinhole calibration was obtained before the surgery using a 3D calibration target, and the image correlation was carried out using the Davis software from LaVision Ltd. Fig. 1 shows an example of the contrast pattern and the full field strain measurements with DIC. There are several obvious restrictions in generating an optimal contrast pattern, and in this case, the pattern was simply applied by the operating surgeon with a sterile marker. Due to the poor quality of the contrast pattern, the displacements were calculated by comparing consecutive images and adding up the incremental displacements. This procedure accumulates errors, but in this case, the sequence of images for each heartbeat was less than 20 so that the errors remained manageable. The subset size in the calculations was 79 and the step size was 10 pixels. In this paper, we present preliminary results from the native heart condition that refers to the images obtained after the sternotomy and before any surgical repairs were done, as well as results obtained from the images obtained after the surgical repairs when the heart has been weaned from the cardiopulmonary bypass.



**Figure 1:** a) An example raw image of the heart, and b) an example of the subsequent full field deformation measurement.

## Results

Fig. 2 shows the longitudinal strain obtained from the surface of the heart using a virtual extensometer attached to the full-field strain measurement data. The images were obtained simultaneously with the ECG signal shown as the blue line in Fig.2. The strain data was synchronized with respect to the ECG signal so that the heartbeat starts from the end of the diastole (maximum volume). The strain as a function of time presents several features and values that are typically used to characterize the functioning of the heart. For the native stage, a small positive systolic strain (number 1. in Figure 2) is observed, but after the surgery, this value is higher and the positive cycle lasts longer. The systolic strain or the maximum compression (number 2. in Figure 2) is close to 20% for the native condition, but only around 15% after the weaning from CPB. The peak positive diastolic strain (number 3. in Figure 2) is actually negative for the native stage, but a clearly positive response is observed after the weaning process. Finally the time to peak, or the duration of the systole (number 4. in Figure 2), is slightly shorter for the native condition compared to that observed for the measurement after the CPB.



**Figure 2:** Longitudinal strain (red) on the heart and ECG (blue) as a function of time a) after sternotomy and b) after weaning from cardiopulmonary bypass.

## Conclusion

The longitudinal strains of the right ventricle were measured with digital image correlation. Based on the measurements, a clear change can be observed in the behaviour and functioning of the heart before and after the surgical repairs and cardiopulmonary bypass. In this case, significant changes were observed in the positive systolic strain, post systolic strain, and positive diastolic strain. The results show that DIC can provide accurate measurements and detect changes in the behaviour of the heart in-vivo.

## References

- [1] M. Hokka, N. Mirow, H. Nagel, M. Irsusi, S. Vogt, and V. Kuokkala, *J. Biomech.* vol. 48 (2015), pp. 2217-2220.
- [2] A. Soltani, S. Curtze, J. Lahti, K. Järvelä, J. Laurikka, M. Hokka, and V.-T. Kuokkala, proceedings of the Annual Meeting of the Society for Experimental Mechanics, Indianapolis, USA, 2017.